

# 1

## Magnetic Resonance Image Characteristics

### Introduction And Overview

Magnetic resonance imaging (MRI) is a medical imaging process that uses a magnetic field and radio frequency (RF) signals to produce images of anatomical structures, of the presence of disease, and of various biological functions within the human body. MRI produces images that are distinctly different from the images produced by other imaging modalities. A primary difference is that the MRI process can selectively image several different tissue characteristics. A potential advantage of this is that if a pathologic process does not alter one tissue characteristic and produce contrast,

it might be visible in an image because of its effect on other characteristics. This causes the MRI process to be somewhat more complex than most imaging methods. In order to optimize an MRI procedure for a specific clinical examination, the user must have a good knowledge of the characteristics of the magnetic resonance (MR) image and how those characteristics can be controlled.

In this chapter we will develop a basic knowledge and overview of the MR image, how the image relates to specific tissue characteristics, and how image quality characteristics can be controlled.

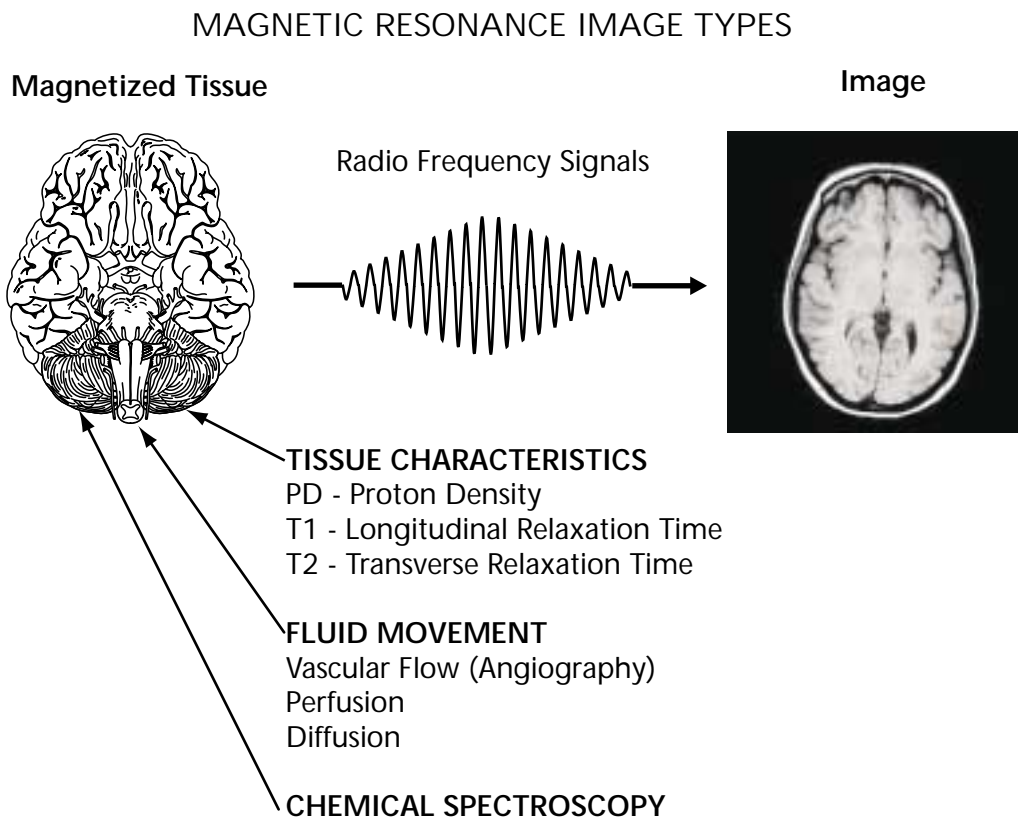
## The MR Image

The MR image displays certain physical characteristics of tissue. Let us now use Figure 1-1 to identify these characteristics and to see how they are related.

The MR image is a display of RF signals that are emitted by the tissue during the image acquisition process. The source of the signals is a condition of magnetization that is produced in the tissue when the patient is placed in the strong magnetic field. The tissue magnetization depends on the presence of magnetic nuclei. The specific physical characteristic of tissue or fluid that is visible in the image depends on how the magnetic field is

being changed during the acquisition process. An image acquisition consists of an acquisition cycle, like a heartbeat, that is repeated many times. During each cycle the tissue magnetization is forced through a series of changes. As we will soon learn in much more detail, all tissues and fluids do not progress through these changes at the same rate. It is the level of magnetization that is present at a special “picture snapping time” at the end of each cycle that determines the intensity of the RF signal produced and the resulting tissue brightness in the image.

MR images are generally identified with specific tissue characteristics or blood conditions



**Figure 1-1.** Physical characteristics of tissue and fluid movement that can be displayed in the magnetic resonance image. MRI can also provide certain chemical information by applying spectroscopy analysis to the RF signals emitted by the tissue.

that are the predominant source of contrast. These characteristics determine the level of tissue magnetization and contrast present at the time the “picture is snapped.” The equipment operator, who sets the imaging protocol, determines the type of image that is to be produced by adjusting various imaging factors.

The characteristics that can be used as a source of image contrast fall into three rather distinct categories. The first, and most widely used, category is the magnetic characteristics of tissues. The second category is characteristics of fluid (usually blood) movement. The third category is the spectroscopic effects related to molecular structure.

At this time we will briefly introduce each of these characteristics to set the stage for the much more detailed descriptions presented later.

## Tissue Characteristics and Image Types

### Proton Density (PD) Images

The most direct tissue characteristic that can be imaged is the concentration or density of protons (hydrogen). In a proton density image the tissue magnetization, RF signal intensity, and image brightness are determined by the proton (hydrogen) content of the tissue. Tissues that are rich in protons will produce strong signals and have a bright appearance.

### Magnetic Relaxation Times — T1 and T2 Images

During an MRI procedure the tissue magnetization is cycled by flipping it into an unstable condition and then allowing it to recover. This recovery process is known as *relaxation*. The time required for the magnetization to relax varies from one type of tissue to another. The relaxation times can be used to distinguish

(i.e., produce contrast) among normal and pathologic tissues.

Each tissue is characterized by two relaxation times: T1 and T2. Images can be created in which either one of these two characteristics is the predominant source of contrast. It is usually not possible to create images in which one of the tissue characteristics (e.g., PD, T1, or T2) is the only pure source of contrast. Typically, there is a mixing or blending of the characteristics but an image will be more heavily *weighted* by one of them. When an image is described as a T1-weighted image, this means that T1 is the predominant source of contrast but there is also some possible contamination from the PD and T2 characteristics.

## Fluid Movement and Image Types

### Vascular Flow

The MRI process is capable of producing images of flowing blood without the use of contrast media. Although flow effects are often visible in all types of images, it becomes the predominant source of contrast in images produced specifically for vascular or angiographic examinations as described in Chapter 12.

### Perfusion and Diffusion

It is possible to produce images that show both perfusion and diffusion within tissue. These require specific imaging methods and are often characterized as functional imaging.

### Spectroscopic and Chemical Shift

The frequency of the RF signals emitted by tissue is affected to a small degree by the size and characteristics of the molecules containing the magnetic nuclei. These differences in frequencies, the chemical shift, can be displayed in images. It is also the basis of MR spectroscopy. Spectroscopy is the process of

using magnetic resonance to analyze the chemical composition of tissue. Spectroscopy makes use of the fact that different molecular structures have different resonant frequencies. Typically, the MR signals from a tissue specimen are sorted and displayed on a frequency scale. The signals from different chemical compounds will appear as peaks along the frequency scale. This leads to their identity and measure of relative abundance.

## What Do You See In An MR Image?

We have discovered that an MR image can display a variety of tissue and body fluid characteristics. However, there are several physical characteristics that form the link between the image and the tissue characteristics described above. Understanding this link gives us a better appreciation of how the tissue characteristics are made visible. We will use Figure 1-2 to develop the link.

### Radio Frequency Signal Intensity

The first thing we see in an image is RF signal intensity emitted by the tissues. Bright areas in the image correspond to tissues that emit high signal intensity. There are also areas in an image that appear as dark voids because no signals are produced. Between these two extremes there will be a range of signal intensities and shades of gray that show contrast or differences among the various tissues.

Let us now move deeper into the imaging process and discover the relationship between RF signal intensity and other characteristics.

### Tissue Magnetization

The condition within the tissue that produces the RF signal is *magnetization*. At this point we will use an analogy to radioactive nuclide

imaging. In nuclear medicine procedures it is the presence of radioactivity in the tissues that produces the radiation. In MRI it is the magnetization within the tissues that produces the RF signal radiation displayed in the image. Therefore, when we look at an MR image, we are seeing a display of magnetized tissue.

We will soon discover that tissue becomes magnetized when the patient is placed in a strong magnetic field. However, all tissues are not magnetized to the same level. During the imaging process the tissue magnetization is cycled through a series of changes, but all tissues do not change at the same rate. It is this difference in rates of change of the magnetization that makes the tissues different and produces much of the useful contrast. This will be described in much more detail later when we will learn that these rates of change are described as magnetic relaxation times, T1 and T2.

It is the level of magnetization at specific “picture snapping” times during the imaging procedure that determines the intensity of the resulting RF signal and image brightness. The MR image is indeed an image of magnetized tissue. Tissues or other materials that are not adequately magnetized during the imaging procedure will not be visible in the image.

### Protons (Magnetic Nuclei)

The next thing we see is an image of protons that are the nuclei of hydrogen atoms. That is why an MRI procedure is often referred to as proton imaging.

The magnetization of tissue, which produces the RF signals, comes from protons that are actually small magnets (magnetic nuclei) present in the tissue. These small magnets are actually the nuclei of certain atoms that have a special magnetic property called a *magnetic moment*. Not all chemical substances have an adequate abundance of magnetic nuclei.

## WHAT DO YOU SEE IN AN MR IMAGE?

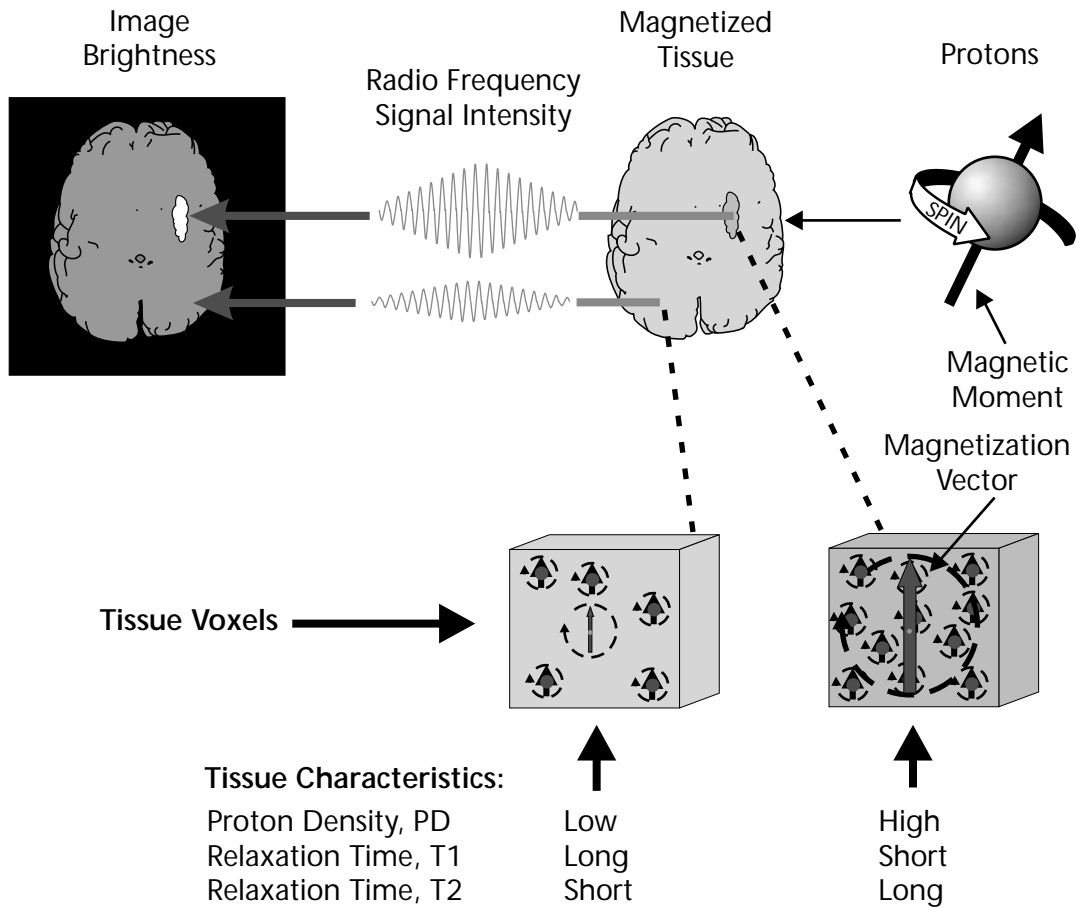


Figure 1-2. The physical characteristics that form the link between the image and the three tissue characteristics.

### Hydrogen

The only substance found in tissue that has an adequate concentration of magnetic nuclei to produce good images is hydrogen. The nucleus of a hydrogen atom is a single proton. Therefore, the MR image is an image of hydrogen. When tissue that contains hydrogen (small magnetic nuclei), i.e., protons, is placed in a strong magnetic field, some of the protons line up in the same direction as the magnetic field. This alignment produces the magnetization in the

tissue, which then produces the RF signal. If a tissue does not have an adequate concentration of molecules containing hydrogen, it will not be visible in an MR image.

### Tissue Characteristics

As we have moved deeper into the imaging process we arrive again at the three tissue characteristics: PD, T1, and T2. It is these characteristics that we want to see because they give us valuable information about the

tissues. These characteristics become visible because each one has an effect on the level of magnetization that is present at the picture snapping time in each imaging cycle. At this time we will briefly describe the effect of each and then develop the process in more detail in Chapters 4 and 5.

### PD (Proton Density)

PD has a very direct effect on tissue magnetization and the resulting RF signal and image brightness. That is because the magnetization is produced by the protons. Therefore, a tissue with a high PD can reach a high level of magnetization and produce an intense signal.

### T1

When the imaging protocol is set to produce a T1-weighted image, it is the tissues with the short T1 values that produce the highest magnetization and are the brightest in the image.

### T2

When the imaging protocol is set to produce a T2-weighted image, it is the tissues with the long T2 values that are the brightest. This is because they have a higher level of magnetization at the picture snapping time.

## Spatial Characteristics

Figure 1-3 illustrates the basic spatial characteristics of the MR image. MRI is basically a tomographic imaging process, although there are some procedures, such as angiography, in which a complete anatomical volume will be displayed in a single image. The protocol for the acquisition process must be set up to produce the appropriate spatial characteristics for a specific clinical procedure. This includes such factors as the number of slices,

slice orientation, and the structure within each individual slice.

## Slices

A typical examination will consist of at least one set of contiguous slices. In most cases the entire set of slices is acquired simultaneously. However, the number of slices in a set can be limited by certain imaging factors and the amount of time allocated to the acquisition process.

The slices can be oriented in virtually any plane through the patient's body. The major restriction is that images in the different planes cannot generally be acquired simultaneously. For example, if both axial and sagittal images are required, the acquisition process must be repeated. However, there is the possibility of acquiring 3-D data from a large volume of tissue and then reconstructing slices in the different planes, as will be described in Chapter 9.

## Voxels

Each slice of tissue is subdivided into rows and columns of individual volume elements, or voxels. The size of a voxel has a significant effect on image quality. It is controlled by a combination of protocol factors as described in Chapter 10 and should be adjusted to an optimum size for each type of clinical examination. Each voxel is an independent source of RF signals. That is why voxel size is a major consideration in each image acquisition.

## Image Pixels

The image is also divided into rows and columns of picture elements, or pixels. In general, an image pixel represents a corresponding voxel of tissue within the slice. The brightness of an image pixel is determined by the intensity of the RF signal emitted by the tissue voxel.

## SPATIAL CHARACTERISTICS

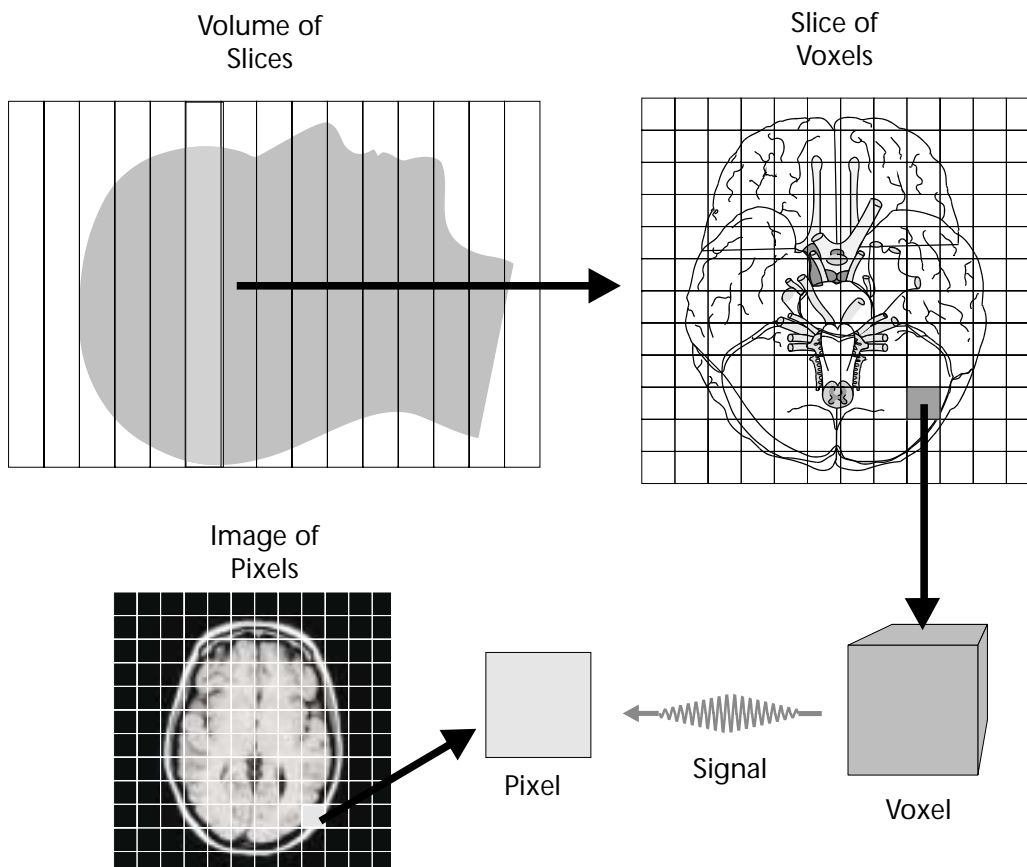


Figure 1-3. The spatial characteristics of MR images.

### Control Of Image Characteristics

The operator of an MRI system has tremendous control over the characteristics and the quality of the images that are produced. The five basic image quality characteristics are represented in Figure 1-4. Each of these image characteristics is affected by a combination of the imaging factors that make up the acquisition protocol.

Not all types of clinical procedures require images with the same characteristics. Therefore, the primary objective is to use an imaging

protocol in which the acquisition process is optimized for a specific clinical requirement.

Although each of the image characteristics will be considered in detail in later chapters, we will introduce them here.

### Contrast Sensitivity

Contrast sensitivity is the ability of an imaging process to produce an image of objects or tissues in the body that have relatively small physical differences or inherent contrast. The contrast that is to be imaged is in the form of

## MAGNETIC RESONANCE IMAGE QUALITY CHARACTERISTICS

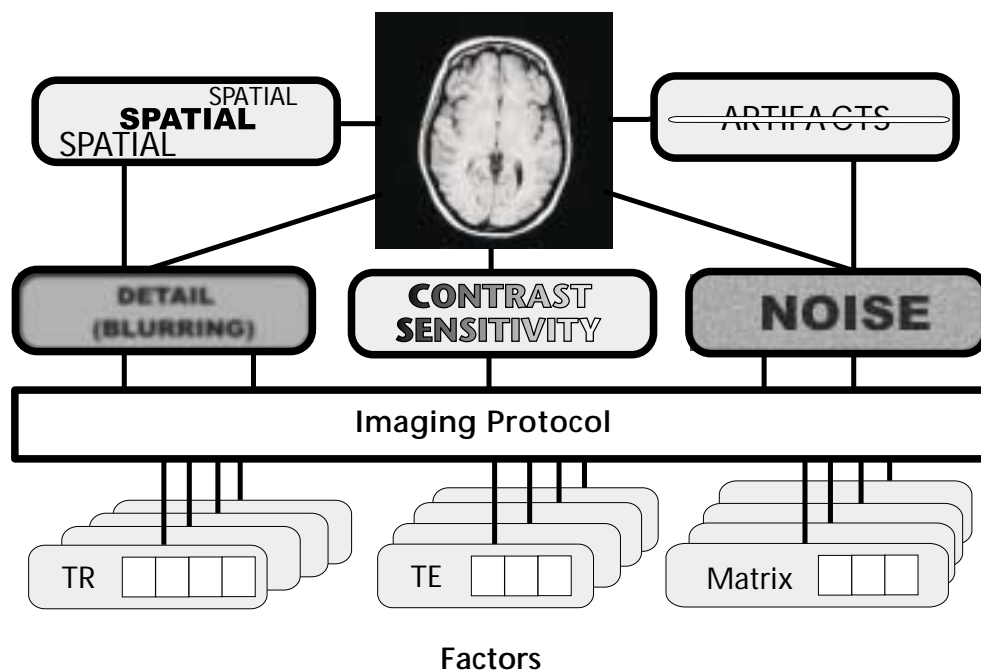


Figure 1-4. Image quality characteristics that can be controlled by the selection of protocol factors.

some specific physical characteristic. In x-ray imaging, including CT (computed tomography), difference in physical density is a principle source of contrast. One of the major advantages of MRI is that it has a high contrast sensitivity for visualizing differences among the tissues in the body because there are several sources of contrast; that is, it has the ability to image a variety of characteristics (PD, T1, T2) as described previously. Also, there is usually much greater variation among these characteristics than among the tissue density values that are the source of contrast for x-ray imaging. If a certain pathologic condition does not produce a visible change in one characteristic, there is the possibility that it will be visible by imaging some of the other characteristics.

Even though MRI has high contrast sensitivity relative to most of the other imaging modalities, it must be optimized for each clinical procedure. This includes the selection of the characteristics, or sources of contrast, that are to be imaged and then adjusting the protocol factors so that the sensitivity to that specific characteristic is optimized. This is illustrated in Figure 1-5.

### Detail

A distinguishing characteristic of every imaging modality is its ability to image small objects and structures within the body. Visibility of anatomical detail (sometimes referred to as spatial resolution) is limited by the blurring that occurs during the imaging process. All medical imaging methods produce images with some



blurring but not to the same extent. The blurring in MRI is greater than in radiography. Therefore, MRI cannot image small structures that are visible in conventional radiographs.

In MRI, like all modalities, the amount of blurring and the resulting visibility of detail can be adjusted during the imaging process. Figure 1-6 shows images with different levels of blurring and visibility of detail. The protocol factors that are used to adjust detail and the associated issues in their optimization will be discussed in Chapter 10.

## Noise

Visual noise is a major issue in MRI. The presence of noise in an image reduces its quality, especially by limiting the visibility of low contrast objects and differences among tissues. Figure 1-7 shows images with different levels of

visual noise. Most of the noise in MR images is the result of a form of random, unwanted RF energy picked up from the patient's body.

The amount of noise can generally be controlled through a combination of factors as described in Chapter 10. However, many of these factors involve compromises with other characteristics.

## Artifacts

Artifacts are undesirable objects, such as streaks and spots, that appear in images which do not directly represent an anatomical structure. They are usually produced by certain interactions of the patient's body or body functions (such as motion) with the imaging process.

There is a selection of techniques that can be used to reduce the presence of artifacts. These will be described in Chapter 14.

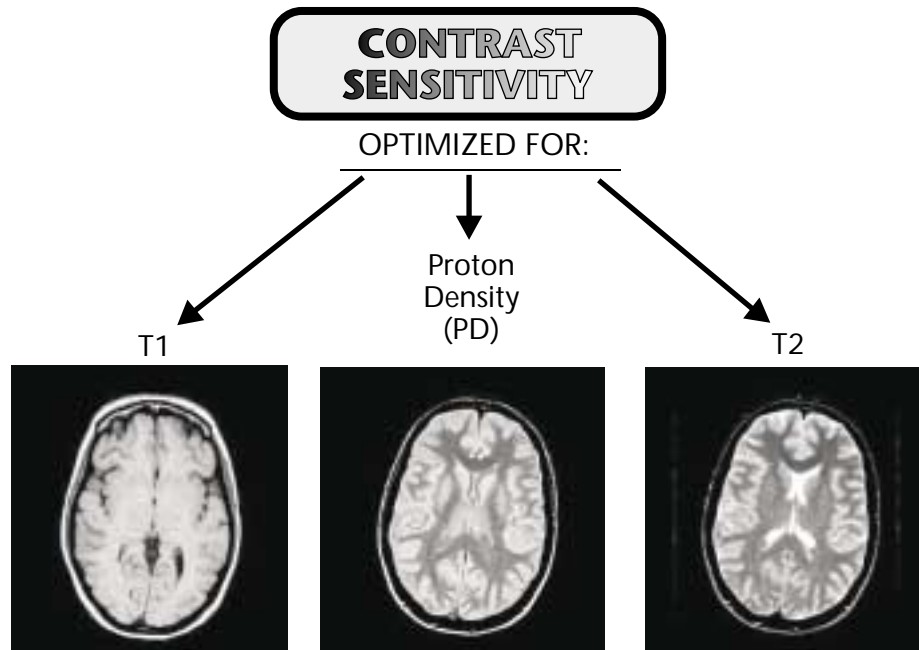


Figure 1-5. The images produced when the contrast sensitivity is optimized for each of the three specific tissue characteristics.

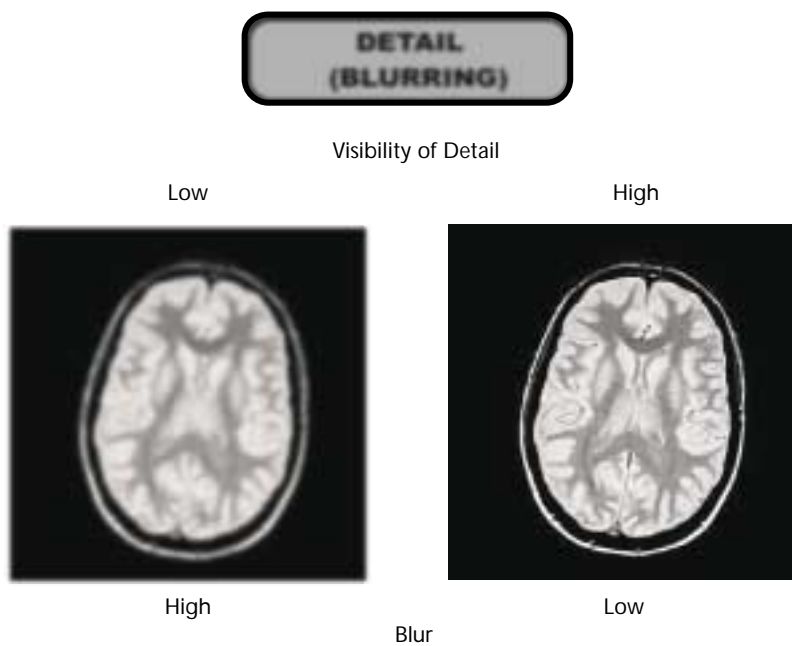


Figure 1-6. Images with different levels of blurring and visibility of anatomical detail.

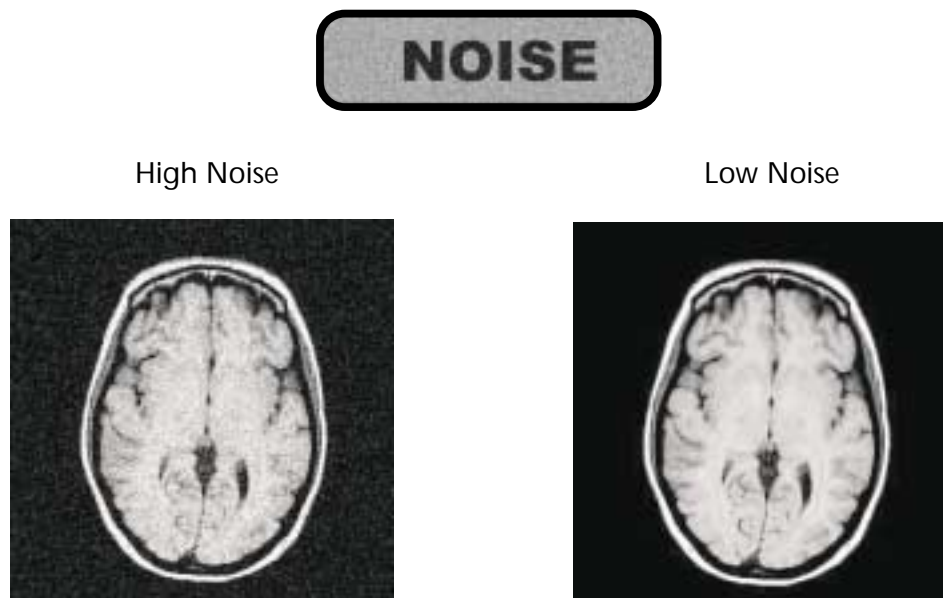


Figure 1-7. Images with different levels of visual noise.

## Spatial

The general spatial characteristics of the MR image were described previously. However, when setting up an imaging protocol the spatial characteristics must be considered in the general context of image quality. As we will discover later, voxel size plays a major role in determining both image detail and image noise.

## Image Acquisition Time

When considering and adjusting MR image quality, attention must also be given to the time required for the acquisition process. In general, several aspects of image quality, such as detail and noise, can be improved by using longer acquisition times.

## Protocol Optimization

An optimum imaging protocol is one in which there is a proper balance among the image quality characteristics described above and also a balance between overall image quality and acquisition time.

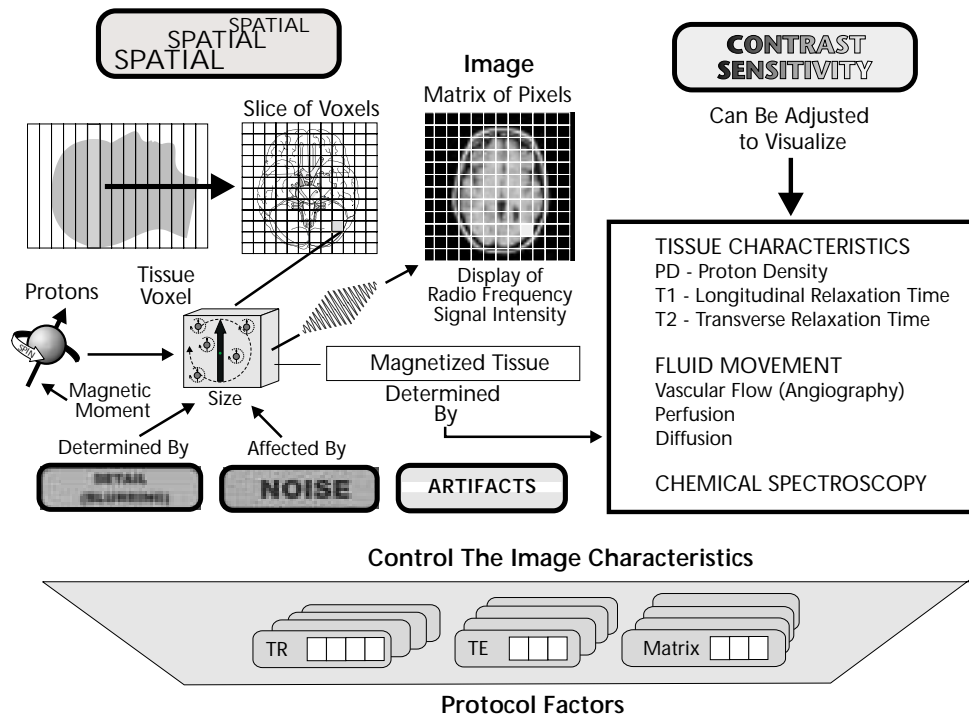
The imaging protocol that is used for a specific clinical examination has a major impact on the quality of the image and the visibility of anatomical structures and pathologic conditions.

Therefore, the users of MRI must have a good knowledge of the imaging process and the protocol factors and know how to set them to optimize the image characteristics.

The overall process of optimizing protocols will be described in Chapter 11.

## Mind Map Summary

### Magnetic Resonance Image Characteristics



The magnetic resonance image is a display of radio frequency signal intensities that are emitted by magnetized tissue during the imaging process. The tissue becomes magnetized because it contains protons that are the magnetic nuclei of hydrogen atoms. When placed in the strong magnetic field, some of the protons align with the field producing the tissue magnetization. The level of magnetization at the time during the procedure when the “picture is snapped” is determined by a variety of tissue and fluid movement characteristics. By adjusting the imaging process it is possible to produce images in which these various characteristics are the principal sources of contrast.

An advantage of MRI is the ability to selectively image a variety of tissue and fluid characteristics. If a specific pathologic condition is not visible when viewing one characteristic, there is the possibility of seeing it by imaging some of the other characteristics.

During the imaging procedure a section of the patient’s body is divided first into slices, and the slices are divided into a matrix of voxels. Each voxel is an independent RF signal source. Voxel size can be adjusted and is what determines image detail and also affects image noise.

The five major image quality characteristics—contrast sensitivity, detail, noise, artifacts, and spatial—can be controlled to a great extent by the settings of the various protocol factors.

MRI is a powerful diagnostic tool because the process can be optimized to display a wide range of clinical conditions. However, maximum benefit requires a staff with the knowledge to control the process and interpret the variety of images.